

10:32 – 10:38 am

**PRESENTER:** Ravi S. Krishnan, MD

**TITLE:** An Alternative Technique for Anchoring Cartilage Grafts along the Alar Rim

**AUTHOR:** Ravi S. Krishnan, MD<sup>1</sup>

**INSTITUTION:** 1. Mohs Surgery, Virginia Mason Medical Center, Seattle, WA, United States

**PURPOSE:** Defects of the nasal ala are commonly encountered by Mohs surgeons. When repairing such defects, it is important to ensure that the alar rim has sufficient structural integrity to prevent an unsightly retraction or notching. Free cartilage grafts are commonly used to support the alar rim and prevent such deformities.

The traditional method of securing a cartilage graft for this purpose involves fixing the cartilage subcutaneously with interrupted or figure-of-eight sutures. While this technique is adequate, it can sometimes be difficult to ensure that the cartilage graft is tightly apposed to the inferiormost portion of the alar rim. If the graft is not perfectly apposed to the inferior alar rim remnant, then subtle retraction may occur despite the fact that a cartilage graft was placed.

In this study, we propose an alternative technique which involves securing the cartilage graft by placing sutures through the skin and/or mucosal surface of the inferior alar rim. These sutures create a sling that has the effect of pulling the cartilage graft securely against the remnant of the alar rim so that retraction of the alar rim will not take place.

**DESIGN:** We performed a review of 20 cases in which cartilage grafts were used to repair inferior alar defects in conjunction with either local flaps or full-thickness grafts.

For these cases, the technique was performed as follows: First, cartilage graft of the appropriate shape and size was harvested by the standard technique and then it was placed along the alar rim. Then two to three 5-0 prolene sutures were placed, starting outside the skin or mucosa and then through the skin/mucosa, around the graft, and then back through the skin/mucosa to create a sling that pulled and secured the graft inferiorly.

Once the cartilage graft was secure, a flap or full-thickness skin graft was performed to complete the repair. The prolene sutures which were anchoring the cartilage graft were removed in 2 weeks.

**SUMMARY:** In our review, all patients were evaluated at 2 weeks, 2 months, and 6-8 months. No significant alar retraction was noticed by either the patients or the surgeon. All patients tolerated the procedure well.

**CONCLUSION:** This technique for anchoring cartilage grafts along the alar rim is easy to perform and ensures that the graft will be precisely placed along the inferiormost portion of the alar rim. It reliably prevents even minimal degrees of alar rim retraction and yields reproducible results.

10:39 – 10:45 am

**PRESENTER:** Timothy L. Parker, MD

**TITLE:** Halo Grafts-Why You Don't Need to Dread Skin Cancers on the Lower Leg Anymore

**AUTHOR:** Timothy L. Parker, MD<sup>1</sup>

**INSTITUTION:** 1. Advanced Derm Surgery, Overland Park, KS, United States

**PURPOSE:** To demonstrate the use of a novel split-thickness skin graft from the surrounding skin of a leg wound to markedly reduce healing time.

**DESIGN:** Leg skin cancers are common especially in the elderly. The resulting wounds following surgery often have great difficulty healing in a timely manner. Second intention healing can take months of care and usual skin grafts create a second wound that heals slowly and is very unpopular with patients. The use of halo grafts will be demonstrated as a technique that is fast, easy, does not create a second wound and is very tolerable for patients while allowing healing of the wound in half the time of second intention healing.

**SUMMARY:** A summary of results of a series of leg wounds following skin cancer excision and reconstruction with halo grafts is demonstrated. From January 2010 to May 2010 there were 12 halo grafts performed on lower leg wounds. The average age of the patients was 71 years. The average defect size was 2.0 cm<sup>2</sup>. The average time for complete healing was 9 weeks (range 5.3-16 weeks). Overgranulation was present in 11/12 wounds during the post-operative period. The healing times were longer than a previous study by Sharad Paul, MD, but still resulted in the wounds healing in approximately half the time of second intention healing without a second donor site wound.

**CONCLUSION:** Halo grafts from the periphery of a leg wound following skin cancer removal are simple and well-tolerated resulting in a superior way to get faster healing.

10:46 – 10:52 am

**PRESENTER:** Paul X. Benedetto, MD

**TITLE:** Intraoperative Mohs Clearance of Advanced Cutaneous Tumors Resected by Otolaryngology: A Collaborative Approach

**AUTHORS:** Paul X. Benedetto, MD<sup>1</sup>, Rahul Seth, MD<sup>2</sup>, Michael A. Fritz, MD<sup>2</sup>, Christine Poblete-Lopez, MD<sup>1</sup>, Allison T. Vidimos, MD<sup>1</sup>

**INSTITUTIONS:** 1. Dermatology, Cleveland Clinic Foundation, Cleveland, OH, United States 2. Otolaryngology, Cleveland Clinic Foundation, Cleveland, OH, United States

**PURPOSE:** Our goal is to report the advantages of Mohs micrographic surgery performed in conjunction with otolaryngology (ENT) in the clearance of advanced cutaneous malignancies traditionally considered beyond the scope of outpatient surgery.

**DESIGN:** We present a retrospective review of 27 cases of advanced cutaneous malignancies cleared with Mohs surgery and concurrently reconstructed by otolaryngology performed at our institution over a 3 year period.

**SUMMARY:** Despite its utility in the extirpation of most facial non-melanoma skin cancers, Mohs surgery can be impractical for very large malignancies in the outpatient setting due to extent of tumor involvement, poor patient tolerance, excessive procedure duration, and difficulty coordinating same-day reconstruction. However, resection with wide margins by ENT also often proves inadequate, owing to discordance between intraoperative frozen sections and permanent pathology reports. Our ENT colleagues report frequently performing elaborate same-day reconstructions after false intraoperative reassurance of negative margins only to discover that residual tumor persists and further resection is required.

We present 27 cases of advanced malignancies with aggressive growth patterns, perineural invasion or extensive involvement of underlying structures jointly excised by one ENT surgeon and processed by two Mohs surgeons. In each case, interdepartmental collaboration aided in achieving our aims: tumor clearance; efficient accurate analysis of frozen sections; avoidance of unduly prolonged general anesthesia; reduction in need for further resection after reconstruction. By involving both teams in preoperative planning our goals were accomplished even in cases of large aggressive tumors.

Planning consisted of preoperative assessment of gross clinical margins and review of available imaging. With patients under general anesthesia, the ENT surgeon initially excised the tumors with wide margins with the goal of achieving a negative first Mohs layer. Next, the Mohs surgeon processed the tumor block as a traditional Mohs layer, sectioning it, inking the cut edges and mapping the tumor on a Mohs map. In this way 100% of the cutaneous and subcutaneous margins of the specimen were processed and analyzed histologically. Any tumor involving underlying structures was resected with standard margins and the surgical specimens were assessed with permanent sections only. Despite the large tumor size, the Mohs team was able to provide intraoperative assurance that the cutaneous margins were indeed negative for residual neoplasm in the time required by the otolaryngologist to harvest free flaps or plan a complex reconstruction. As a result, an increased clearance rate was achieved efficiently without subjecting the patient to any undue risk. Furthermore, the chance of the final pathology report contradicting intraoperative frozen section interpretation was mitigated.

**CONCLUSION:** For advanced facial cutaneous malignancies, we recommend a collaborative approach to tumor extirpation with intraoperative Mohs tissue sectioning and histopathology interpretation in conjunction with ENT tumor debulking and facial reconstruction. This affords the reconstructive surgeon greater assurance of margin control, and provides the patient with an optimized same-

day reconstruction. We plan to demonstrate our methods and results with pre-, intra- and postoperative photographs, corresponding histopathology and illustrative radiographic imaging.

Demographics	
Number of patients / tumors	27 / 30
Mean age, years (SD)	68.7 (12.2)
Males, n (%)	14 (53.8%)
Pathology	
BCC, n (%)	14 (46.7 %)
SCC, n (%)	10 (33.3%)
Trichoblastic carcinoma, n (%)	1 (3.3%)
Dermatofibrosarcoma, n (%)	1 (3.3%)
Squamous Porocarcinoma, n (%)	1 (3.3%)
Tumor Characteristics / Indications for Intra-Op Mohs	
Mean Area Resection per Lesion, cm <sup>2</sup>	63.9
Perineural Invasion	12 (40.0%)
Recurrent Lesion	19 (63.3%)
Transplant History	4 (13.3%)
Anatomic Involvement	
Nasal / Central Face Involvement	12 (40.0%)
Temple/Parotid Involvement	8 (26.7%)
Auricular/Mastoid Involvement	3 (10.0%)
Scalp Involvement	3 (10.0%)
Forehead Involvement	2 (6.7%)
Invasion of dura mater	1 (3.3%)
Mohs Details	
Mean number of layers to clearance, n (SD)	2.1 (0.98)
Additional Therapies Performed	
Free flap reconstruction, n (%)	9 (30.0%)
Post-op Radiation, n (%)	3 (10.0%)

**10:53 – 10:59 am**

**PRESENTER:** Tanya R. Humphreys, MD

**TITLE:** Assessment of Postoperative Pain Following Mohs Micrographic Surgery and Reconstruction

**AUTHORS:** Boonyapat Limthongkul, MD<sup>1</sup>, Faramraz Samie, MD, PhD<sup>1</sup>, Tanya R. Humphreys, MD<sup>1</sup>

**INSTITUTION:** 1. Dermatology, Thomas Jefferson University, Philadelphia, PA, United States

**PURPOSE:** While most patients experience minimal discomfort during the procedure, postoperative pain following Mohs micrographic surgery has not been well characterized. The objective of this study was to evaluate the amount of postoperative pain following Mohs micrographic surgery and to determine if the degree of pain was correlated with factors such as tumor location, size, number of sites, age or gender of the patient.

**DESIGN:** One hundred and fifty-eight patients with skin cancer who were treated with Mohs micrographic surgery were included in this study. Information was recorded for each study participant including age, sex, diagnosis, tumor location, number of sites, number of Mohs excision stages and type of repair performed. A daily log was given to the patient to record the amount of pain experienced using the Wong-Baker pain scale (0=none, 5= severe) and any analgesics (acetaminophen or acetaminophen with hydrocodone) that were taken on the day of surgery and 8 consecutive days after.

**SUMMARY:** The majority of patients reported some degree of pain on day 0 (mean pain score 1.97, SD 1.456) and day 1 (Mean pain score 1.15, SD 1.201). However, the fraction of patients reporting pain and the severity of that pain diminished steadily thereafter. By day 7, only twenty-five patients (16%) were experiencing any pain, with 21 of them reporting only a little pain (score of 1). Acetaminophen was used by about half the patients on day 0 (n=77, 55%), which rapidly declined each subsequent day. Only 26 patients (16%) required prescription analgesics on the day of surgery (day 0) and less on subsequent days. Greater reported pain was significant for scalp procedures and multiple same day procedures. No significant correlation with age or gender was noted.

**CONCLUSION:** Postoperative pain after Mohs micrographic surgery was associated with only mild to moderate pain on the day of surgery and the first post operative day. Most pain was effectively managed by oral acetaminophen with a minority of patients requiring prescription analgesics. Surgery on the scalp was significantly more painful than other sites. Prospective patients can be reassured that Mohs micrographic surgery and reconstruction is well tolerated and associated with only mild to moderate discomfort postoperatively.

11:00 – 11:06 am

**PRESENTER:** Irene J. Vergilis-Kalner, MD

**TITLE:** Freehand Split-thickness Skin Grafts to Repair Nasal Defects

**AUTHORS:** Irene J. Vergilis-Kalner, MD<sup>1,2</sup>, Leonard H. Goldberg, MD<sup>2,3</sup>, Jennifer Landau, BS<sup>2</sup>, Megan Moody, MD<sup>2</sup>, Paul M. Friedman, MD<sup>2,4</sup>, Arash Kimyai-Asadi, MD<sup>2,3</sup>

**INSTITUTIONS:** 1. Skin Laser and Surgery Specialists of NY and NJ, New York, NY, United States 2. Derm Surgery Associates, Houston, TX, United States 3. Departments of Dermatology, Weill Cornell Medical College, Methodist Hospital, Houston, TX, United States 4. Department of Dermatology, University of Texas, Houston, TX, United States

**PURPOSE:** Freehand split-thickness skin grafts (STSG) are a convenient, effective, and reliable reconstruction option for partial thickness dermal defects on the nose. A flexible blade is used to harvest the grafts, which have a high take and very low necrosis rate.

The objective of this study was to assess clinical outcomes of freehand STSGs on the nose as a function of the location and size of the defect and the location of the donor site.

**DESIGN:** 118 freehand STSGs on the nose were performed after Mohs surgery. Clinical outcomes were evaluated based on live and photographic assessments.

**SUMMARY:** 75 grafts were evaluated at short- (mean 3.1 months) and long-term (mean 12.3 months) follow-up visits. The average graft size was  $3.1 \pm 2.8$  cm<sup>2</sup>. Adverse cosmetic effects included telangiectasia, step deformity, erythema, dyspigmentation, depression, and micro-keratotic cysts, which resolved with incision and drainage. The overall outcome was best for grafts used to repair flat surfaces. In general, smaller grafts had better cosmetic results than their larger counterparts in the short-term follow-up, with no difference being appreciated in the long-term follow-up.

**CONCLUSION:** The use of freehand STSGs for reconstruction of partial thickness dermal defects on the nose is an efficient, reliable, and cosmetically acceptable repair option.



Figure 1. Defect site

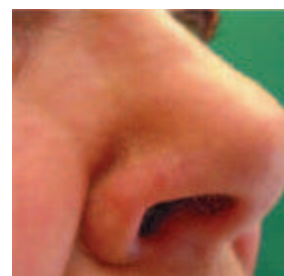


Figure 2. Follow-up of split thickness skin graft

11:07 – 11:13 am

**PRESENTER:** Kenny J. Omlin, MD

**TITLE:** The Utility of the Pursestring Stitch for the Repair of Challenging Lip Defects Following Mohs Surgery

**AUTHOR:** Kenny J. Omlin, MD<sup>1,2</sup>

**INSTITUTIONS:** 1. Mohs Surgery, Kaiser Permanente, Vacaville, CA, United States 2. Dermatology, University of California at Davis, Medical Center, Sacramento, CA, United States

**PURPOSE:** Repair of lip defects following Mohs surgery presents a unique challenge to the surgeon. When the surgical defect involves both vermillion and cutaneous subunits the repair can appear imposing. Maintenance of oral sphincter competence is of utmost importance.

Additionally, aesthetics play an integral role in lip reconstruction. Precise alignment of the vermilion border to avoid eclabium is particularly important. Techniques described in the literature include primary closure, wedge repair and a variety of elaborate flaps. We present a novel technique utilizing the pursestring stitch for the repair of lip defects that cross both vermilion and cutaneous boundaries.

**DESIGN:** 32 patients underwent Mohs surgery for removal of either squamous cell carcinoma or basal cell carcinoma involving the lip. Following tumor extirpation, 24 lesions involved both vermilion and cutaneous subunits. Defect size ranged between 0.5cm x 0.5cm to 3.5cm x 1.5cm, and involved a wide variety of locations including the columella and oral commissure. Immediate repair was performed in all cases utilizing the pursestring stitch. After meticulously undermining the surgical site, an intradermal, absorbable pursestring stitch was placed. Patients were evaluated at 1 week, 1 month, and 2 months.

**SUMMARY:** After 1 month all patients achieved full oral competence and excellent aesthetic outcome (Figures 1 and 2).

**CONCLUSION:** The pursestring stitch provides an excellent repair option for lip defects following Mohs surgery. The challenging nature of defects that involve both vermilion and cutaneous subunits are readily handled with this repair. The circumferential nature of the pursestring stitch and resulting centralized vector forces likely play an integral role in the success of this repair in this otherwise challenging location. Further research is needed to determine the mechanism by which the vermilion and cutaneous surfaces communicate to avoid the development of eclabium.

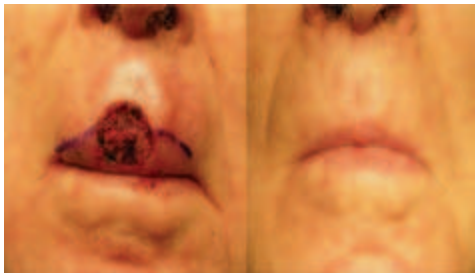


Figure 1. a. Defect b. Final outcome

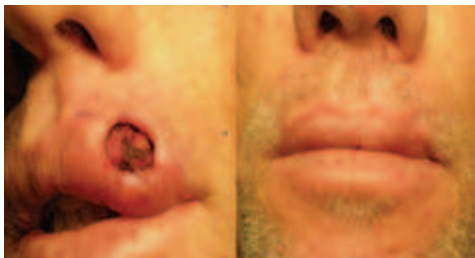

Figure 2. a. Defect b. Final outcome

11:14 – 11:20 am

**PRESENTER:** Joseph W. McGowan, IV, MD

**TITLE:** Electronic Mohs Mapping

**AUTHORS:** Joseph W. McGowan, IV, MD<sup>1</sup>, Heidi B. Donnelly, MD<sup>1</sup>

**INSTITUTION:** 1. Dermatologic Surgery, Dayton Skin Surgery Center, Dayton, OH, United States

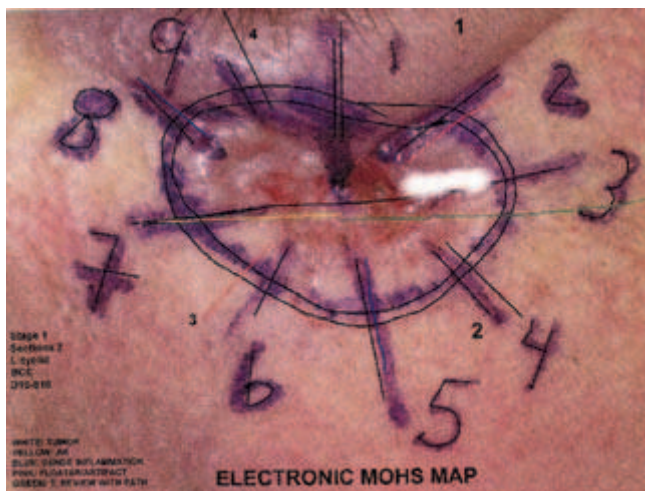

**PURPOSE:** To identify: (1) the technique, (2) design, (3) accuracy, (4) color coding scheme and (5) the relative advantages/disadvantages involved in the use of electronic Mohs mapping (EMM).

**DESIGN:** The authors describe a Mohs mapping presentation on EMM in the private practice setting. We will include a discussion of the logistics of template construction using the “image boiler” which can be superimposed on digitized clinical images to produce an electronic “composite” map. The “image boiler” program, accessible through the electronic medical record (EMR) system, allows the histotechnologist to apply concentric circles or geometric shapes to closely reproduce a clinical defect. In essence, a cartoon image is produced. Histotechnologists then use color coding schemes that correspond to dye colors used on microscopic sections for orientation. Physician mapping also utilizes colors with the airbrush-stroke tool to differentiate histologic findings on the EMM. Red indicates tumor; yellow indicates actinic keratosis/diffuse actinic damage; green indicates areas of inflammation; pink designates floaters/artifacts. EMMs can be printed on plain mapping paper for preview by dermatologists- or fellows-in-training.

**SUMMARY:** Limitations and relative advantages are discussed. Considerations include ease/accuracy for the Mohs surgeon, in-training resident physician, fellow and histotechnologist. A hard copy of the EMM can be generated for purposes of educational value: the Mohs fellow and/or resident dermatologist can construct his own Mohs map independent of the attending Mohs surgeon. Color coding schemes offered in EMM are more efficient than symbolic schemes used in hard-copy Mohs maps, minimizing errors and maximizing ease in interpretation of histologic specimens. Accessioning is also electronic and is a safeguard against inaccuracy. Electronic assignment of patient identifiers also minimizes error in faulty Mohs map assignment. Troubleshooting software- and hardware-specific obstacles are addressed. Digitized composite EMMs are a user-friendly, efficient, organized way of processing, assimilating and displaying clinical and histologic data during Mohs micrographic surgery.

**CONCLUSION:** EMM (electronic Mohs mapping) is essential for a Mohs surgeon’s successful utilization of the Electronic Medical Record system. Limitations in the use of EMM include training of histotechnologists, accessibility, computer malfunction and inefficiency during the transition period. However, a computerized catalog of the EMMs proves useful in patient follow up and clinical mapping.

EMMs are a suitable surrogate for hard-copy Mohs maps, and 'composite' EMMs introduce a further dimension of accuracy and efficiency to geometrically complex defects.



11:21 – 11:27 am

PRESENTER: Omar A. Ibrahimi, MD, PhD

TITLE: Free Cartilage Grafting With Second Intention Healing For Defects on the Distal Nose

AUTHORS: Omar A. Ibrahimi, MD, PhD<sup>1</sup>, Tracy M. Campbell, MD<sup>1</sup>, Summer Youker, MD<sup>1</sup>, Daniel B. Eisen, MD<sup>1</sup>

INSTITUTION: 1. Dermatology, UC Davis, Sacramento, CA, United States

PURPOSE: Defects of the distal nose, particularly the nasal ala, pose a reconstructive challenge due to the lack of loose adjacent tissue and proximity to a free margin. Cartilage struts are often advocated as part of any nasal reconstruction that occurs within 5 mm of the alar margin, to minimize the risk of alar margin distortion or nasal valve collapse. Traditional dogma has been to cover these struts with a concurrent flap or skin graft. We report our experience using free cartilage grafts in combination with second intention healing for nasal ala defects.

DESIGN: In this retrospective case series study, 16 nasal ala defects repaired using free cartilage grafting with second intention healing over the 1-year study period were identified. Detailed data on the quality of the scar, post-operative complications, free margin distortion, functional impairments, and patient satisfaction were recorded. Digital images were also shown to an experienced fellowship-trained Mohs surgeon who did not perform the reconstructive procedure and was asked to assess the overall aesthetic outcome using a 5-point score ranging from poor to excellent.

SUMMARY: Seventeen subjects were identified who had reconstruction using free cartilage grafts with second intention healing during the 1-year study period. Only 16 subjects returned for follow up following the procedure. Complications were common, but minor. Five (~31%) subjects had subtle contour depressions, three (~18%) subjects had post-operative ear pain at the donor site lasting up to 10 days, two (~12%) subjects had excessive granulation tissue, and one (~6%) subject had a hypertrophic scar. There were two occurrences (~12%) of mild alar notching but no occurrences of significant alar margin distortion or nasal valve dysfunction. In terms of aesthetic outcome, six (~43%) were assessed as having excellent aesthetic outcomes, six (~43%) were very good, and two (~14%) were good, while two subjects are awaiting overall aesthetic outcome assessment. All sixteen subjects reported satisfaction on follow-up evaluation.

CONCLUSION: Free cartilage grafting with second intent healing allows for facile, single-step repair of distal nose defects with high patient satisfaction and aesthetically-pleasing results.

11:28 – 11:34 am

**PRESENTER:** J. Michael Wentzell, MD

**TITLE:** Dorsal Nasal Flap for Full Thickness Defects of the Nose

**AUTHOR:** J. Michael Wentzell, MD<sup>1</sup>

**INSTITUTION:** 1. Billings Clinic, Billings, MT, United States

**PURPOSE:** Repair of full thickness distal nasal defects traditionally involves a multi-layered reconstruction involving nasal vestibular lining, cartilage graft and external lamellar flap, usually a multi-staged paramedian forehead flap. But in selected cases this approach can be replaced with a single stage dorsal nasal flap employing no nasal vestibular lining flap or cartilage graft. This approach can produce results superior to other reconstructive choices. The purpose of this presentation is to describe the application of the single stage dorsal nasal flap as a complete reconstruction for full thickness defects of the distal nose.

**DESIGN:** Large, full thickness Mohs surgery defects of the distal nose are presented. The stepwise surgical reconstruction of these defects using the dorsal nasal flap is described. Novel and useful design modifications are presented. Postoperative results are reviewed.

**SUMMARY:** Over twelve years of experience has demonstrated the reliability and utility of the Dorsal Nasal Flap as a successful one-stage reconstruction in full thickness defects of the distal nose.

**CONCLUSION:** The Dorsal Nasal Flap can be used as a one-stage, single flap reconstruction of large, full thickness defects of the distal nose. The final cosmetic and functional results can be equivalent to or superior to results obtained by other methods. Patient acceptance is high, results are sustained over time and follow-up procedures have not been necessary. The dorsal nasal flap is an effective method for reconstructing selected full thickness defects of the distal nose.

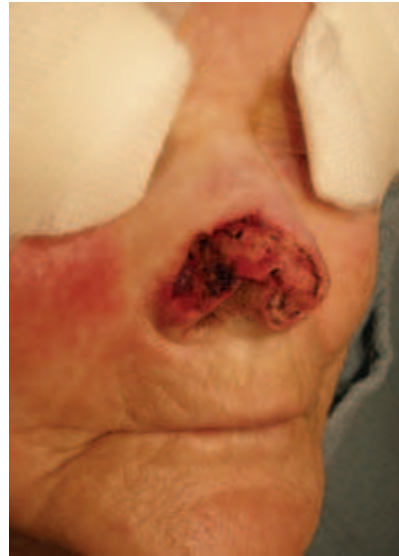

Figure 1. Large, Full-Thickness Defect before Single-Stage Dorsal Nasal Flap.



Figure 2. Long Term Follow-Up. No Additional Intervention.

11:35 – 11:41 am

**PRESENTER:** Jared J. Lund, MD

**TITLE:** Sliding and Non-Sliding Z-Plasties: Applications in Vertical Lip Reconstructions and Beyond

**AUTHORS:** J. Michael Wentzell, MD<sup>1</sup>, Jared J. Lund, MD<sup>1</sup>

**INSTITUTION:** 1. Cutaneous Oncologic Surgery, Billings Clinic, Billings, MT, United States

**PURPOSE:** The purpose of this presentation is to demonstrate the advantages of Z-plasties in vertical lip reconstructions. A secondary purpose of this article is to explore six distinct causes of lip deformities that arise during reconstructive surgery, and how those complications can be averted by employing either a traditional Z-plasty or a new modification we term the sliding Z-plasty.

**DESIGN:** We explore the planning and execution of lip reconstructions using traditional Z-plasties and sliding Z-plasties. This analysis utilizes case reports, original illustrations and an in-depth review of the spatial dynamics of lip reconstruction.

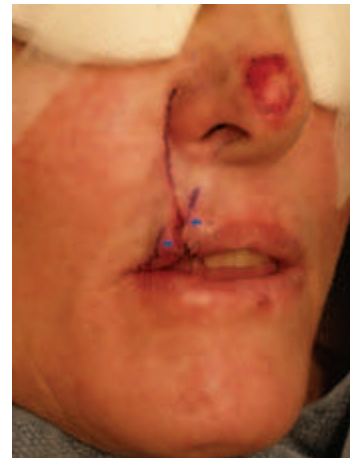Ultimately, this analysis compels us to challenge the commonly held dogma of lip reconstruction and suggest a paradigm shift in the thinking of lip wound realignment.

**SUMMARY:** Lip reconstructions frequently have vertical incision lines that may or may not approach or cross the vermilion border. These reconstructions follow lines of relaxed skin tension. Never-the-less, potential complications can adversely affect the final result.

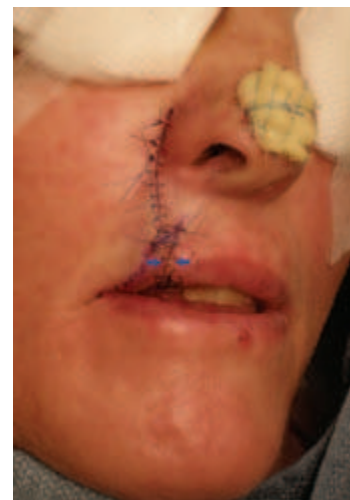These complications include: A) A cosmetically noticeable step-off at the vermilion border due to misalignment at the time of surgery. B) A functional step-off or misalignment of the wet line. C) A fat lip deformity as a result of externally rolling the labial mucosa. D) Scar contracture. E) A trigone deformity. This is a design-related complication that looks similar to the vermilion displacement of a scar contracture. F) An exaggerated creasing of the vertical scar caused by repeated contraction of the orbicularis oris muscle.

A Z-plasty during the initial reconstruction may avert or minimize these complications. This Z-plasty might be of traditional design or a variation termed the sliding Z-plasty.

**CONCLUSION:** Either traditional or sliding Z-plasties can improve the final outcome of vertical lip reconstructions while averting or mitigating six distinct potential complications associated with vertical lip repairs.



Lip wound repaired in vertical fashion- wet line is approximated first maintaining the original arc of curvature of the lip and avoiding the fat lip deformity. A step-off at the vermilion border results (4 mm- note blue arrows). A sliding Z-plasty is designed with a shorter central arm compared to the two lateral arms. This unique design compels a sliding displacement of one side of the central arm relative to the other until the 3 arms of the Z-plasty are equal in length. As the flaps are transposed, this relative sliding realigns displaced anatomic borders adjacent to the Z-plasty.



Sliding Z-plasty fine tunes alignment of vermilion border and disguises vertical incision line. Note that after the sliding Z-plasty is performed, the vermilion border laterally is aligned with the border medially (blue arrows).

4:03 – 4:11 pm

**PRESENTER:** Kathleen M. Rossy, MD**TITLE:** *Difficulty with Surgical Site Identification: What Role does it play in Dermatology?***AUTHORS:** Kathleen M. Rossy, MD<sup>1,2</sup>, Naomi Lawrence, MD<sup>2</sup>**INSTITUTIONS:** 1. Princeton Center for Dermatology, Princeton, NJ, United States 2. Cooper University Hospital, Cherry Hill, NJ, United States**PURPOSE:** The potential for wrong-site surgery is a growing concern in the field of medicine. The purpose of this study was to determine the incidence of difficulty with surgical site identification in dermatology and the possible confounding factors associated with it.**DESIGN:** A single center prospective study with multivariable analysis was conducted to evaluate the percentage of patients who had difficulty correctly identifying their surgical site on the day of Mohs micrographic surgery. The sample size consisted of 329 patients with 333 skin cancers. Patients included in the study were over the age of 18 years old, presented for Mohs surgery, and were able to consent for themselves. All cases were evaluated during the allotted period from 4/1/2009- 2/9/2010. All patients included in the study had previously had an office or phone consult where they either reported being able to identify their sites or they were sent back to the referring physician for confirmation prior to their surgical date. On the day of Mohs, data collection forms were used to record the amount of difficulty associated with identification and possible confounding factors. The data sheets were designed to collect information regarding: degree of difficulty in identification, location, age, gender, history of skin cancer, history of multiple treatments on the same day, visual impairment, the presence of referring physician notes or photos, whether lesions were in a location visible to the subject, time between biopsy and surgery date, and the outcome on the day of surgery.**SUMMARY:** A total of 333 cases were evaluated, and 9% (30) were unable to confidently identify their surgical sites. The majority of cases (88.5%) were located on the head and neck. When comparing subjects that were able to identify their surgical sites and those that were not, there was a statistically significant difference ( $p=0.035$ ) in the percentage of lesions residing in a location visible to the subject. Those who were able to see their biopsy sites were 3.5 times ( $p=0.01$ ) more likely to identify their surgical site. Of the patients evaluated, only 47.6% of subjects had accompanying chart notes, which consisted of a photo, diagram, and/or measurements. On closer evaluation of the chart notes, 5% of these cases were photographs and 23% of these had high quality diagrams. Although a delay in treatment of greater than 3 months from the original biopsy site was higher among those with difficulty in identifying their surgical site, this was not found to be statistically significant. The remaining factors evaluated (gender, age, location, visual impairment, history of multiple treatments on the

same day, and history of skin cancer) did not prove to be significantly different among those who were able to identify their site and those who were not.

**CONCLUSION:** Our study shows a significant issue in site identification which puts us at risk of performing wrong site surgery. We have shown that at least 9% of patients presenting for Mohs surgery, despite pre-procedure screening, are unable to confidently identify their surgical sites. We have also evaluated confounding factors that, in our clinical experience, have contributed to difficulty with biopsy site identification. The results confirmed that lesions located in sites visible to the patient were more likely to be confidently identified on the day of surgery. In our experience, a history of previous procedures, widespread actinic damage, and a longer delay until surgery are factors that also contribute to difficulty with site identification. The results did not support these findings, but we believe with a larger sample size these trends would become more evident.

4:11 – 4:19 pm

**PRESENTER:** Oliver Wisco, DO**TITLE:** *Modified Mohs Micrographic Surgery for Lentigo Maligna or Melanoma In-Situ of the Head and Neck Utilizing Overnight En Face Permanent Section Analysis: A Ten-Year Experience of 202 Cases***AUTHORS:** Oliver Wisco, DO<sup>1</sup>, Krista E.B. Reis, PA-C<sup>1</sup>, Lisa M. Cohen, MD<sup>2</sup>, Donald J. Grande, MD<sup>1</sup>**INSTITUTION:** 1. Mohs Surgery, Mystic Valley Dermatology, Stoneham, MA, United States 2. Caris Life Dermatopathology, Newton, MA, United States**PURPOSE:** An on-going debate exists on how to surgically manage lentigo maligna and melanoma in-situ of the head and neck. Standard of care has historically required 5mm margins be used when conducting traditional excision for these malignancies, but recent studies have indicated the need for more precise margin control. Mohs micrographic surgery has become an increasingly effective treatment modality, but its use is controversial due to the difficulty of evaluating melanocytes on frozen sections. MART-1 staining has improved diagnostic accuracy, but reported case series to date have been limited. In order to avoid the frozen section evaluation perils, the use of modified Mohs micrographic surgery with rapid overnight en face permanent paraffin section processing, with or without MART-1 staining, is gaining acceptance. The modified Mohs technique allows for both margin control and permanent paraffin section analysis, thus avoiding the frozen section analysis restrictions. This is particularly important with the institution of the American Academy of Dermatology's upcoming guidelines of care for the management of primary cutaneous melanoma. The recent draft version of the guideline considers permanent paraffin section evaluation as the "gold standard" when excising lentigo maligna/melanoma in situ or invasive melanoma.



**DESIGN:** Similar to the data for traditional Mohs surgery for lentigo maligna and melanoma in-situ, the research on the modified Mohs technique is also limited. To address this issue, we performed a retrospective chart review study on our experience using the modified Mohs technique for lentigo maligna and melanoma in-situ from January 2000 through January 2010. During this time period, 202 cases were identified. The primary focus of the study was to determine the recurrence rate using this technique, with additional examination on the size of the margins needed to remove the tumor. A subgroup analysis of 33 patients pretreated with Imiquimod for six to eight weeks prior to the use of the modified Mohs technique was also performed.

**SUMMARY:** The review of our 202 cases of lentigo maligna or melanoma in-situ of the head and neck treated with the modified Mohs technique identified a total of six recurrences. When including only cases that had not undergone prior surgical treatment (n=186), four recurrences were found. In the Imiquimod subgroup, there were no recurrences. Further analysis of the 202 cases revealed that the average margin size needed to clear the tumor was 0.68cm, with an average of 1.66 layers required. The average first layer margin taken was 0.42cm. Of those cases with a positive first layer (n=89), the average percentage of the first layer's peripheral margin found to have residual tumor was 47%.

**CONCLUSION:** This is the largest case series to date of the modified Mohs technique for lentigo maligna or melanoma in-situ of the head and neck. This retrospective study reinforces the effectiveness of combining a permanent section analysis with a technique that efficiently employs margin control.

4:19 – 4:27 pm

**PRESENTER:** Holly H. McCoppin, MD

**TITLE:** *The Clinical Spectrum of Atypical Fibroxanthoma in Solid Organ Transplant Recipients: A Collective Experience*

**AUTHORS:** Holly H. McCoppin, MD<sup>1</sup>, Dan L. Christiansen, PGY-1<sup>2</sup>, Thomas Stasko, MD<sup>2</sup>, Juan-Carlos Martinez, MD<sup>3</sup>, Carl V. Washington, Jr., MD<sup>1</sup>, Marc D. Brown, MD<sup>4</sup>, Fiona O'Reilly Zwald, MD<sup>5</sup>

**INSTITUTIONS:** 1. Dermatology, Emory University, Atlanta, GA, United States 2. Dermatology, Vanderbilt University, Nashville, TN, United States 3. Dermatology, Mayo Clinic - Jacksonville, Jacksonville, FL, United States 4. Dermatology, University of Rochester, Rochester, NY, United States 5. Dermatology & Division of Transplantation, Emory University, Atlanta, GA, United States

**PURPOSE:** We describe the clinical spectrum of atypical fibroxanthoma (AFX) and its more aggressive deeper variant, now termed undifferentiated pleomorphic sarcoma (UPS) in solid organ transplant recipients (SOTRs). We believe this tumor should be added to the list of cutaneous malignancies for which our chronically immunosuppressed organ transplant patients are at higher risk. We also wish to evaluate whether

these tumors demonstrate a more aggressive clinical course in the SOTRs.

**DESIGN:** A retrospective chart review of AFX and UPS, previously called malignant fibrous histiocytomas (MFH), in SOTRs was designed and implemented at two universities. Cases from two clinics were also included. A literature search included all cases previously published in the English language (seven articles, 11 cases). Data was collected, tabulated, and compared with published data regarding AFX/UPS in non immunosuppressed patients.

**SUMMARY:** The majority of patients had undergone renal transplantation (7/15; 47%). The average age of the patient at time of AFX presentation was 58 years, which is younger than the 69 to 72 years typically seen in immunocompetent patients who present with AFX (Fretzin et al 1979, Ang et al 2009). The average interval between transplantation and presentation of AFX was 11 years. There were higher rates of local recurrences (40%) and metastases (27%) in the cases of AFX in immunosuppressed patients than has been reported in immunocompetent individuals. Thirteen out of the 15 tumors were on the head and neck region, with five on the scalp. This mirrors the pattern of tumor growth seen in the immunocompetent population. Rates of recurrence were higher in those treated with excision (50% recurred) versus Mohs micrographic surgery (20% recurred). Five patients (33%) in this series succumbed to their disease.

**CONCLUSION:** This series demonstrates that AFX with progression to UPS or spindle cell squamous cell carcinoma may occur more frequently in SOTRs, with a greater risk for recurrence, metastatic disease and mortality. In SOTRs with AFX, aggressive treatment with Mohs micrographic surgery (MMS) is warranted to minimize the chance for local recurrence and metastasis. UPS or recurrent tumors should be staged appropriately and treated aggressively with MMS or wide excision, and may benefit from wide field radiation therapy. Reduction of immunosuppression should be considered. Immunohistochemical evaluation by an experienced dermatopathologist is recommended to rule out progression to other spindle cell tumors, especially in the setting of metastasis. Further studies are needed to determine whether histologic features, immunostains or tumor markers may help to further define management and prognosis of these tumors in SOTRs.

4:27 – 4:35 pm

**PRESENTER:** Yaohui G. Xu, MD, PhD

**TITLE:** *Eccrine Porocarcinoma Treated by Mohs Micrographic Surgery: Report of Ten Cases with Literature Review*

**AUTHORS:** Yaohui G. Xu, MD, PhD<sup>1</sup>, Juliet L. Gunkel, MD<sup>1</sup>, B. Jack Longley, MD<sup>1</sup>, Stephen N. Snow, MD<sup>1</sup>

**INSTITUTION:** 1. Dermatology, University of Wisconsin, Madison, Madison, WI, United States

**PURPOSE:** Eccrine porocarcinoma (EPC) is an uncommon malignant tumor of the intraepithelial or acrosyringium portion of the eccrine glands that can behave aggressively. Approximately 250 cases of EPC have been reported since the original description by Pinkus in 1963. Clinical management of this cancer remains a daunting challenge. The majority of patients with EPC have been treated by standard local excision with undefined margins. Local recurrence has been documented in approximately 20% of the cases, regional metastases 20%, and distant metastases 10%. Mortality rate is up to 80% in patients with metastases. Mohs micrographic surgery (MMS) has been shown to be a promising surgical intervention for early-stage EPC.

**DESIGN:** This is a retrospective case series of all patients of EPC who were treated by MMS between 1984 and 2010 in the Mohs surgery clinic of our institution. Additionally, all reported cases of EPC managed by MMS in the world's literature were reviewed. The clinical characteristics and outcome of each case are summarized.

**SUMMARY:** In our clinic between 1984 and 2010, 11 patients were diagnosed with EPC and 10 treated with MMS. To the best of our knowledge, this is the single largest case series of EPC treated with MMS. The average age at diagnosis was 65 years (range, 36-86 years). Seventy percent of the patients were male. All patients were Caucasians. Among the 10 lesions, three were located on the lower extremities (30%), three on the chest (30%), and four on the head and neck area (40%), with one each on the nasal bridge, chin, antihelix, and forehead. The average size of the lesions was 17 mm (range, 7-47 mm). The average duration of the growth was 2.9 years (range, 2 weeks-12 years). Four of our ten patients had recurrent tumors; lesions being treated by prior local excision, cryotherapy or topical fluorouracil cream. Clinical presentations varied, resembling non-melanoma skin cancer, seborrheic keratosis, or pyogenic granuloma. Initial histological diagnosis was misinterpreted in three cases as basal cell carcinoma or squamous cell carcinoma. The average Mohs stages required to achieve a tumor-free plane were 2.2. The average post-operative size was 33 mm (range, 11-78 mm). In our series, there have been no local recurrences, distant metastasis or disease specific death to date, with an average follow-up of 47 months (range, 3 months to 7 years). Two patients died from other causes. Only one patient had regional lymph node metastasis and received adjuvant therapy. This patient with EPC on the chest developed left axillary lymph node metastasis 8 months following Mohs surgery. She underwent lymphadenectomy and electron beam radiation therapy, and subsequently had no evidence of recurrence locally or regionally at 7-year follow up. The rest of the 9 patients received MMS as monotherapy. We reviewed an additional 15 cases compiled from case reports and case series in the literature. The average age at diagnosis was 65 years (range, 36-79 years). Forty percent of the patients were male. Three patients were African Americans. Among the 15 lesions, seven were located on

the lower extremities (47%), three on the trunk, and five on the head and neck area, with one each on the antihelix, scalp, temple, and two on the eyelid. The average size of the lesions was 15 mm (range, 5-45 mm). The average duration of the growth was 5.6 years (range, 6 weeks-20 years). Tumor status was not clearly stated in most of the cases; two patients had recurrent lesions following standard surgical excision. The average Mohs stages required to achieve a tumor-free plane were 1.8. None had adjuvant therapy. Thirteen of the 15 patients for whom follow-up was available had seen no local recurrences, regional or distant metastasis to date, with an average follow-up of 20 months (range, 2 months-4 years). One patient died from other causes.

Excluding two patients for whom no follow-up data was stated, a total of 23 patients treated by MMS (10 from our series and 13 from others) had shown no local recurrences, distant metastasis or disease specific death over an average follow-up period of 32 months. One patient from our series had regional lymph node metastasis but remained with no evidence of recurrence 7 years post-operatively.

**CONCLUSION:** MMS has a 100% success rate in 23 cases of EPC with an average follow-up period of 32 months. This compares favorably to standard local excision in which an approximately 80% success rate was observed. Although MMS may be the best initial treatment for EPC, patients must be monitored closely for local recurrence, regional and distant metastasis.

4:35 – 4:43 pm

**PRESENTER:** Matthew Donaldson, MD

**TITLE:** Trends in Mohs Utilization in 2009: An Analysis of the 5% Sample Medicare Claims Data

**AUTHORS:** Matthew Donaldson, MD<sup>1</sup>, Brett M. Coldiron, MD, FACP<sup>1</sup>

**INSTITUTION:** 1. TriHealth Good Samaritan/The Skin Cancer Center, Cincinnati, OH, United States

**PURPOSE:** Epidemiologic data suggest the United States is in the midst of a skin cancer epidemic. Recent analyses estimate over 3.5 million cases of non-melanoma skin cancer were treated in the US in 2006. Consequently, Mohs surgery utilization has increased significantly over the past decade. Cases have surged to over 520,000 in 2008 in the Medicare population alone. We evaluate the most recent Medicare claims data to estimate volume of Mohs performed by Mohs surgeon and by region.

**DESIGN:** Data from the 5% sample Medicare claims set are queried for codes 17311-5 for 2004, 2007, and 2009. Data is stratified by provider to estimate number of cases per Mohs surgeon. Data will be further stratified by provider type and state. The ratio of 17311:17312 and 17313:17314 per UPIN/NPI will be presented. Modifiers -51 and -59 attached to 17311, 17313 will be analyzed to determine frequency of multiple site, same-day surgeries. Volume of repair

codes (12001-13153, 14000-14350, 15400-15420, 15570-15738, 15740, 15760, 15050-15261, 40500-40530) billed per UPIN/NPI billing Mohs will be calculated.

**SUMMARY:** 2004 analyses showed 1490 providers billing for Mohs. Estimates of Mohs volume ranged from 20 to 3080. A far left shifted curve demonstrated 52% of surgeons performed fewer than 200 cases.

Further data analysis is underway and will be complete upon receipt of 2009 Medicare claims data. Dermatologists are expected to bill nearly all Mohs cases. Correlation, if any, between additional stages and volume/types of repairs with total volume of Mohs by provider and state will be presented. This study is limited to Medicare data only. It provides an imprecise estimate of cases given random 5% sampling. However, the large number of Mohs cases performed and lack of alternative data sources make such an analysis useful.

**CONCLUSION:** A strongly left-shifted bell curve for Mohs cases per provider was seen in 2004. This trend is expected to be replicated, and exaggerated, in 2007 and 2009. This left shift and right sided plateau likely reflects a bimodal distribution between ACMS-trained and non-trained surgeons. A marked increase in Mohs utilization has been seen over the past decade. This is occurring in the context of an explosion of skin cancer incidence. However, the volume of cases performed by provider and region is not well known. Some data regarding the number of cases needed for Mohs proficiency in a fellowship context have been reported. In the context of limited funding for health care and increasing utilization, appropriate use of Mohs and maximizing cost-effective use will become more important.

4:43 – 4:51 pm

**PRESENTER:** Todd V. Cartee, MD

**TITLE:** Histologic Evaluation of Surgical Margins in Mohs Micrographic Surgery: Quantification of Margin Distance with Each Section of a Mohs Stage and a Survey of Standard Practices among Mohs Surgeons

**AUTHORS:** Todd V. Cartee, MD<sup>1</sup>, Gary D. Monheit, MD<sup>1</sup>

**INSTITUTION:** 1. Total Skin and Beauty Dermatology Center, Birmingham, AL, United States

**PURPOSE:** Based on a 2003 survey, the majority of Mohs surgeons examine 3-9 sections from each processed piece of tissue. When the first or most peripheral section, "the true margin," reveals tumor or when all sections are tumor free, the determination of margin status is unambiguous. However, in a significant minority of cases, no tumor is demonstrable in the initial section only to find cancer lurking in "deeper" cuts. This common quandary is especially challenging because of the dearth of literature to inform the dermasurgeon's evaluation of margin status in such cases. From anecdotal reports, varying opinions exist on how many tumor-free sections are necessary to conclude that margin negativity has been achieved and a given patient will enjoy the 99%

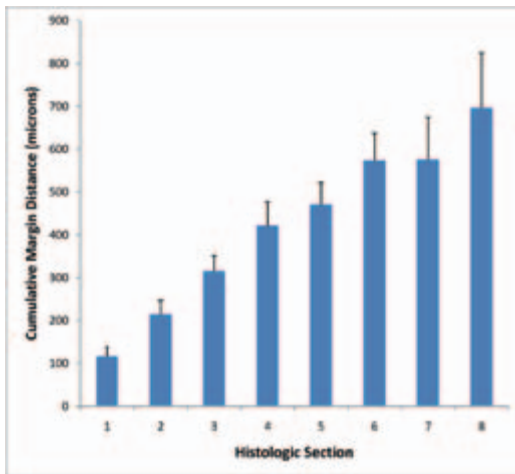
cure rate promised by Mohs micrographic surgery (MMS) for primary basal cell and squamous cell carcinoma. This study seeks to provide some empiric data on the association between margin distance and each histologic section of a Mohs stage. We also designed a survey to document the disparate approaches to this clinical question among Mohs surgeons and examine how certain histologic and anatomic considerations impinge on their decision-making.

**DESIGN:** 3 to 4 primary basal cell and squamous cell carcinomas from the head and neck, which are undergoing MMS, are selected each operative day to include in a prospective study. Our histotechnologists record the cryotome thickness setting and number of cryotome rotations from the moment the tissue is engaged until the first section is applied. They then record the same data between each section applied to a slide until all sections are mounted for a given stage. We are also recording margin status, initial positive section, whether an additional layer was obtained, and the status of the second layer. The target sample size is 200 tumors.

The second part of this study consists of a web-based survey of all members of the American College of Mohs Surgery. The survey was initially piloted among 5 academic Mohs surgeons with experience in survey research. After their feedback was incorporated, the final survey includes 8 questions collecting information on basic demographics and practice characteristics and then explores how the respondent assesses margin status in a variety of clinical scenarios.

**SUMMARY:** Analysis of preliminary results shows that on average 117 microns of tissue has been discarded before the initial histologic section from a Mohs stage is mounted. The margin distance is over 0.5 mm by the sixth section (Mean 574 microns). Once the target sample size is reached, statistical analysis will be performed and presented at the ACMS meeting. An ongoing survey will complement this empiric data with an assessment of the prevailing methodology employed by Mohs surgeons in determining margin status when positivity is confined to sections deep to the "true margin." Finally, we will present at the meeting our second stage positivity rate on additional layers obtained in our practice on these cases.

**CONCLUSION:** Given that an initial 2 mm margin from the clinical border of a tumor is a standard approach for MMS for uncomplicated primary keratinocyte cancers, by the 6th histologic section, on average over 25% of this narrow margin distance has already been "cleared." If positivity first appears in these deeper sections, the surgeon may derive comfort from knowing that a significant margin distance has been achieved. While a definitive answer to this question will require long-term prospective, local recurrence data, the second stage positivity rate in cases of isolated deep positivity will provide some relevant immediate information. An analysis of the standard practices among ACMS members may also prove valuable in developing consensus guidelines regarding this previously unexplored oncologic dilemma.



4:51 – 4:59 pm

**PRESENTER:** Joshua A. Tournas, MD**TITLE:** Patient Specific Factors Influencing Incidence of High-Risk Histologic Features in Cutaneous Squamous Cell Carcinoma (cSCC) – A Retrospective Pilot Study**AUTHORS:** Maulik M. Dhandha<sup>3</sup>, Joshua A. Tournas, MD<sup>1</sup>, Eric S. Armbrecht, PhD<sup>2</sup>, Scott W. Fosko, MD<sup>1</sup>**INSTITUTIONS:** 1. Dermatology, Saint Louis University, Saint Louis, MO, United States 2. Outcomes Research, Saint Louis University, Saint Louis, MO, United States 3. School of Medicine, Saint Louis University, Saint Louis, MO, United States**PURPOSE:** Cutaneous squamous cell carcinoma (cSCC) accounts for 20% of cutaneous malignancies and is the second leading cause of cancer in Caucasians. Histologic features of cSCC portending a higher risk of metastasis have been well-described, and include perineural invasion, perineural inflammation, lymphovascular invasion, poorly differentiated tumor, and acantholytic tumor. The current study aims to identify which preoperative and intraoperative factors predict high-risk histologic behavior under the microscope.

Local metastasis of cSCC usually occurs within the first two years after diagnosis, although late presentation up to 8 years has also been reported. The management of metastatic disease is difficult and the prognosis is often quite poor. Within our institution patients with high risk cSCC are usually managed in a multidisciplinary approach from the onset, something that is not uniformly practiced across academic medical centers. It is hoped that the findings of this study and subsequent expansions will allow detection of those high risk tumors with metastatic potential earlier in the course of treatment so appropriate referrals and investigations can be made.

**DESIGN:** Patient and tumor specific information was collected from a total of 391 patients treated in our institution in 2008 and 2009. Patient specific information included gender, occupation, immune status, use of sunscreen, exposure to radiation, and use of tanning bed. Tumor specific

information included type of cSCC, time elapsed before presentation at clinic, primary vs. recurrent, laterality, site, associated symptoms, visual appearance (scar vs. clinical tumor), pre- and post-operative size, number of Mohs stages until clearance, depth of Mohs defect, perineural inflammation, perineural invasion, and lymphovascular invasion. High risk histologic factors were defined as tumors with at least one of the following: perineural invasion, perineural inflammation, lymphovascular invasion, acantholytic tumor, or poor degree of differentiation.

Statistical analysis was performed using SPSS software (SPSS Inc., Chicago). The tumors were divided into histologically low risk and high risk groups based on the above criteria. T-test for independent sample for means was used for continuous variables and chi-square tests were used for categorical variables. Differences were considered significant at  $\alpha \leq 0.05$ .**SUMMARY:** Statistically significant differences in incidence of high risk histologic findings were found with larger pre-operative size, larger post-operative size, increasing number of Mohs stages needed to clear tumor, and tumor penetrating tissue layers deeper than dermis and fat. Interestingly, tanning bed use was found to be inversely related to high risk histologic findings, with more high risk tumors among non-users.

No significant difference was found in the proportion of low risk and high risk tumor incidence with regard to gender, indoor vs. outdoor occupation, radiation exposure, immune status, sunscreen use, primary vs. recurrent tumor, presence of clinical tumor at time of surgery, laterality, or body site.

**CONCLUSION:** The current pilot study represents all cSCC patients treated during the two years 2008 and 2009 in our institution. Interesting correlations particularly between tumor "width" and tumor "depth" and histologic aggressiveness may help target early interventions in the future with regard to screening for metastasis. It is our hope that identifying such patients early in the course of their disease will lead to increased detection of early or occult metastatic disease and lead to better patient outcomes via early intervention and definitive treatment.

Limitations of the current study include smaller sample size, given the fact that by the aforementioned criteria approximately 15% or 59 tumors qualified as histologically high risk. Factors considered likely to be related to high risk features such as recurrence and tanning bed use similarly were infrequently seen as well, which may or may not be true with a larger sample size. Plans are underway to expand our database retrospectively, which may in turn increase the power of some of our analyses and further refine and support the results obtained from the current data.

4:02 – 4:10 pm

PRESENTER: Kurtis B. Reed, MD

**TITLE:** *The Rising Incidence of Malignant Melanoma among Young Adults***AUTHORS:** Kurtis B. Reed, MD<sup>1</sup>, Jerry D. Brewer, MD<sup>1</sup>, Lawrence E. Gibson, MD<sup>1</sup>, Kariline Bringe, BS<sup>2</sup>, Crystal Pruitt, BS<sup>2</sup>, Christine M. Lohse, BS<sup>3</sup>**INSTITUTIONS:** 1. Department of Dermatology, Mayo Clinic, Rochester, MN, United States 2. Mayo Medical School, Rochester, MN, United States 3. Statistics, Mayo Clinic, Rochester, MN, United States**PURPOSE:** This epidemiologic study estimated the incidence of malignant melanoma in young adults 15-39 years old, in the County, from 1970-2009. The overall incidence of malignant melanoma is increasing in both adults and children. While the incidence of melanoma among young adults has been reported from national cancer registries, no population-based study has yet estimated the incidence among this age group. This study provides data regarding the population-based incidence of melanoma among patients 15-39 years old, and reports trends in the change in incidence.**DESIGN:** The County is an ideal setting for epidemiologic studies. The vast majority of medical care is provided by a limited number of providers. The Rochester Epidemiology Project (REP) is a linkage of medical data from almost all sources of medical care available to the local population of the County.

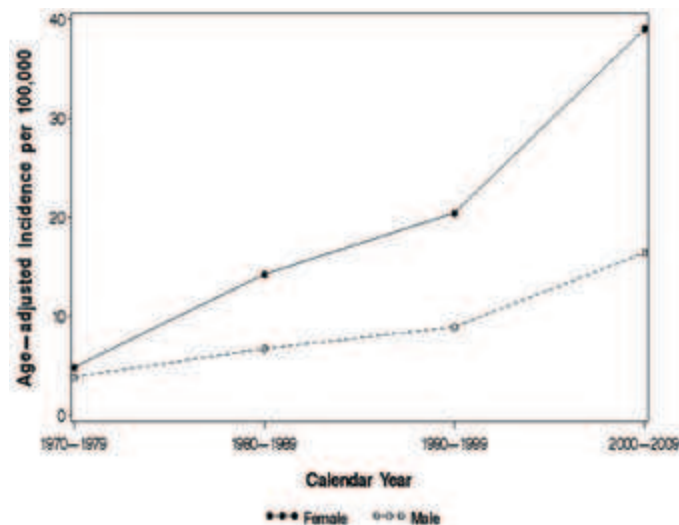
The County residents were identified from the REP databases with a confirmed first lifetime diagnosis of cutaneous melanoma between 15 and 39 years old, with date of diagnosis between January 1, 1970 and December 31, 2009. Age- and sex-specific incidence rates per 100,000 person-years were calculated, with the denominator obtained from decennial census data during this period. The relationships between the incidence of malignant melanoma and age at diagnosis, sex, and calendar year of diagnosis were assessed by fitting generalized linear models. Incident cases were grouped into four calendar year intervals (1970-1979, 1980-1989, 1990-1999, 2000-2009). Disease-specific survival was estimated using the Kaplan-Meier method. Associations of calendar year of diagnosis with death from disease were evaluated using Cox proportional hazards regression models and summarized with hazard ratios and decade specific mortality rates.

**SUMMARY:** The population-based incidence of melanoma among young adults has increased from approximately 4.3/100,000 people in the 1970's to 27.6/100,000 in the 2000's. This increase is most marked among young females, with an approximately 8-fold increase in incidence from the 70's to the 2000's, compared to a 4-fold increase among young men.

The overall estimated disease-specific 5-year survival was 97%. 5-year survival increased from an estimated 91% in

the 1970's to 100% in the 2000's. The hazard ratio for the association of calendar year of diagnosis with death from malignant melanoma was 0.91 (95% CI 0.85 – 0.98;  $p=0.013$ ), indicating that each 1-year increase in calendar year of diagnosis was associated with a decreased risk of death from melanoma. There were no statistically significant interactions among age at diagnosis, sex, and calendar year of diagnosis.**CONCLUSION:** The incidence of malignant melanoma among young adults is increasing exponentially. This increase is most pronounced among young females. While the incidence is increasing, the risk of disease-specific death is decreasing, suggesting possible improved surveillance, earlier treatment, and increased awareness and education.

This retrospective, population-based study was not designed to assess potential risk factors associated with the increased incidence. Other investigators have found that certain high-risk behaviors, such as excessive sun exposure and artificial indoor ultraviolet tanning, are increasingly common among adolescents and young adults, and may contribute to the findings in this study.



4:10 – 4:18 pm

PRESENTER: Kate V. Viola, MD, MHS

**TITLE:** *The Use of Mohs Micrographic Surgery for the Treatment of Non-melanoma Skin Cancers in the Medicare Population***AUTHORS:** Kate V. Viola, MD, MHS<sup>1</sup>, Mamta B. Jhaveri<sup>2</sup>, Ryan B. Turner, MD<sup>1</sup>, Daven N. Doshi, MD<sup>1</sup>, Cary P. Gross, MD<sup>3</sup>**INSTITUTIONS:** 1. Dermatology, Albert Einstein College of Medicine, Bronx, NY, United States 2. University of Maryland School of Medicine, Baltimore, MD, United States 3. Cancer Outcomes, Policy, and Effectiveness Research (COPPER) Center, Yale University School of Medicine, New Haven, CT, United States

**PURPOSE:** Mohs micrographic surgery (MMS) is associated with low recurrence rates and optimal preservation of normal tissue. The American Academy of Dermatology has set forth guidelines for the use of MMS in patients with skin cancer where adequate excision and negative margins is essential. Little is known about current physician practices for patients with non-melanoma skin cancers (NMSC) undergoing surgical treatment. Our objective was to identify Medicare utilization rates of MMS and other surgical interventions for the treatment of NMSC over time, as well as to identify patient, tumor and geographic determinants associated with treatment choice.

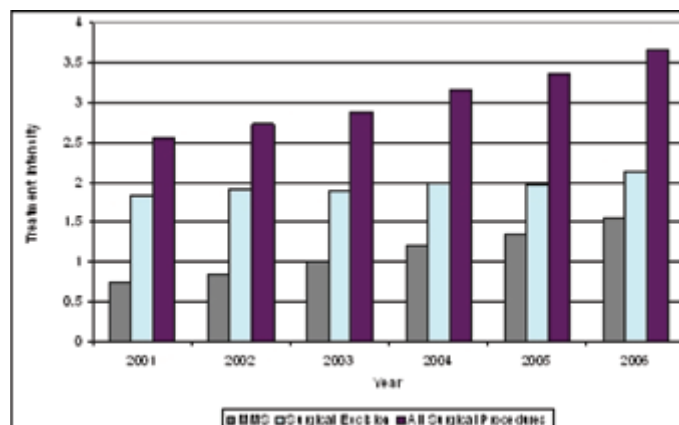
**DESIGN:** We performed a retrospective review of Medicare beneficiaries receiving surgical intervention for the treatment of NMSC from 2001 through 2006 utilizing a 5% random sample of Medicare claims data from the Surveillance, Epidemiology and End Results (SEER) database, representing 26% of the US population and 16 national cancer registries. Our cohort included patients who had ICD codes for NMSC and CPT codes for surgical treatment of NMSC including MMS, wide excision, and simple excision. We performed a bivariate analysis between surgical procedure types (MMS versus other surgical excision) for variables including age, gender, race, tumor location, and geographic region. We also calculated the Mohs surgeon density by SEER region in 2004 and current 2010 density by state.

**SUMMARY:** There were 26,931 persons surgically treated for NMSC from 2001 to 2006, of which 9,802 (36%) received MMS. From 2001 to 2006, the total utilization of surgical treatment increased, primarily due to the increase in MMS over time. In 2001, every 0.7 of 100 Medicare beneficiaries received MMS treatment for NMSC. This number doubled by 2006 (1.5 of 100 beneficiaries). A similar percentage of men and women received MMS (37%, 36% respectively); however a higher proportion of MMS was performed in younger individuals. MMS comprised >50% of all surgeries performed on the head and neck compared to 9-12% of the surgeries performed on the trunk and extremities. Atlanta had the highest proportion of NMSC patients treated with MMS (45%). SEER Regions with similar utilization rates included New Jersey (43%) and Los Angeles (42%). Areas with lower MMS utilization included Louisiana (11%), Hawaii (19%), and New Mexico (23%). Mohs surgeon density within the SEER regions was highest in the San-Jose Monterey region and Rural Georgia (0.142 and 0.103 surgeons per 1,000 Medicare beneficiaries respectively); whereas Detroit and Los Angeles County had the lowest density of Mohs surgeons (0.003 and 0.007, respectively). When plotting surgeon density versus MMS utilization by SEER region, we demonstrated an inconsistent correlation between surgeon density and MMS utilization rates. In our bivariate analysis, age, race, regional demographics and lesion location were significantly associated with utilization of MMS for skin cancer treatment (all  $p < 0.001$ ).

**CONCLUSION:** Our study demonstrated that 36% of all Medicare recipients with NMSC were surgically treated with

MMS between 2001 and 2006. The number of Medicare beneficiaries receiving MMS for NMSC doubled over this time period. We also found significant differences in utilization rates depending on lesion location, favoring MMS when treating the face. Geographical utilization significantly varied by SEER region, although the density of Mohs surgeons did not consistently correlate with MMS utilization rates. To our knowledge this is only study examining the national utilization pattern of MMS for NMSC.

Figure 1. Annual Treatment intensity for each surgical type.



Treatment intensity was calculated by dividing the total number of each procedure by the total number of Medicare beneficiaries each year multiplied by 100.

4:18 – 4:26 pm

**PRESENTER:** Adam Ingraffea, MD

**TITLE:** The Significance of Floaters in the Nicks of Mohs Frozen Sections

**AUTHORS:** Rawn Bosley<sup>1</sup>, Hugh M. Gloster, Jr., MD<sup>1</sup>, Adam Ingraffea, MD<sup>1</sup>

**INSTITUTION:** 1. University of Cincinnati, Cincinnati, OH, United States

**PURPOSE:** The purpose of this study is to determine the clinical significance of “floaters” within the nicks (score marks) of Mohs frozen sections and whether their presence necessitates further surgical excision.

**DESIGN:** During microscopic examination of frozen sections during Mohs surgery, the surgeon may notice islands of tumor cells “floating” within the orientation nicks. These “floaters” frequently induce the surgeon to excise more tissue because of reluctance to conclude that a patient is tumor-free with the continued presence of tumor cells on the frozen section, despite the theoretical and highly probable possibility that tumor cells were implanted from the surface of the specimen to the deep margin by the #15 blade or half razor blade during accentuation of the nicks. The nicks are often accentuated prior to frozen section processing to permit adequate penetration of colored dye into the tissue, which improves visualization during microscopic examination. It has

been the author's practice to take an additional layer during Mohs surgery if a floater is seen in one of the nicks during microscopic examination.

Frozen sections from 40 patients who underwent Mohs micrographic surgery for basal cell carcinoma were included in the study. All frozen sections, which were examined by the author, were noted to have islands of basal cell carcinoma within one of the inked nicks. Once a "floater" was located microscopically, it was marked on the Mohs map and an additional 1 mm layer of tissue was excised around and under corresponding nick on the wound edge of the patient. This additional layer of tissue was then taken to the lab for traditional horizontal section tissue processing, except the histotechnician was instructed to cut through and prepare sections of the entire tissue block to search for the presence of residual tumor.

**SUMMARY:** After microscopic examination, none of the 40 additional frozen sections were found to contain residual basal cell carcinoma.

**CONCLUSION:** This study provides evidence that floaters in the nicks of Mohs frozen sections do not indicate residual tumor in the patient and are probably implanted during accentuation of the nicks. The presence of residual tumor cells within nicks on frozen sections should not induce the Mohs surgeon to take an additional layer of tissue, thus permitting further conservation of normal tissue, which is one of the main advantages of Mohs micrographic surgery.

4:26 – 4:34 pm

**PRESENTER:** Heidi Anderson-Dockter, MD

**TITLE:** Diagnostic Utility of Cytokeratin 17 Immunostaining in Morpheaform Basal Cell Carcinoma and for Detecting Single Tumor Cells at the Margin

**AUTHORS:** Heidi Anderson-Dockter, MD<sup>1</sup>, Todd Clark, MD<sup>1</sup>, Jisun Cha, MD<sup>1,2</sup>, Satori Iwamoto, MD, PhD<sup>1,2</sup>, David Fiore<sup>1,2</sup>, Vincent Falanga, MD<sup>1,3</sup>

**INSTITUTIONS:** 1. Dermatology and Skin Surgery, Roger Williams Medical Center, Providence, RI, United States 2. NIH Center of Biomedical Research Excellence, Roger Williams Medical Center, Providence, RI, United States 3. Dermatology, Boston University School of Medicine, Boston, MA, United States

**PURPOSE:** The morpheaform subtype of BCC often presents a diagnostic histological challenge, and its true margin or extent may be difficult to determine with accuracy. This tumor may also be difficult to distinguish from other adnexal neoplasms having a more benign clinical course. Previous published work has shown that cytokeratin 17 (K17) expression is increased in basal cell carcinoma (BCC). Our aim was to first confirm the uniform and marked expression of K17 in BCC, across the subtypes of superficial, nodular and morpheaform variants. Secondly, we analyzed the expression of K17 in BCC and compared this to two other but benign adnexal neoplasms.

**DESIGN:** Tissue specimens from each tumor category (the three BCC subtypes, desmoplastic trichoepithelioma, and trichoblastoma) were randomly collected unselectively and were immunolabeled and scored for K17 expression by intensity and extent of immunostaining.

**SUMMARY:** Our results indicate that K17 is a very useful marker in the identification and outlining of BCC. Moreover, in morpheaform BCC, K17 immunostaining was able to clearly detect individual putative tumor cells (78% of specimens) well away from the dermal tumor strands and margins that otherwise had initially seemed well defined by hematoxylin and eosin staining alone. In addition, we report that the increased expression of K17 in morpheaform BCC is capable (100% of specimens;  $p < 0.0001$ ) of distinguishing this tumor from desmoplastic trichoepithelioma, a neoplasm that often mimics BCC clinically and histologically.

**CONCLUSION:** We propose that our findings with K17 immunostaining could improve the diagnostic and clinical management of patients with these tumors.

4:34 – 4:42 pm

**PRESENTER:** Jeremy S. Bordeaux, MD, MPH

**TITLE:** Increased Dermatologist Density Associated with Reduction in Melanoma Mortality

**AUTHORS:** Savina Aneja<sup>1</sup>, Sanjay Aneja<sup>3</sup>, Jeremy S. Bordeaux, MD, MPH<sup>1,2</sup>

**INSTITUTIONS:** 1. Case Western Reserve School of Medicine, Cleveland, OH, United States 2. Dermatology, University Hospitals Case Medical Center, Cleveland, OH, United States 3. Yale University School of Medicine, New Haven, CT, United States

**PURPOSE:** We sought to determine the association between dermatologist density and melanoma mortality in US counties. We also examined the effect of age, race, education, income, unemployment rate, health insurance rate, density of primary care physicians, melanoma incidence, county demographics (metropolitan vs. non metropolitan), access to hospitals with oncologic services and health professional shortage area classification on melanoma mortality.

**DESIGN:** Data were collected from the Area Resource File, US Centers for Disease Control, and National Cancer Institute's Surveillance, Epidemiology, and End Results and National Program for Cancer Registries. Multivariate analysis was performed to determine factors that are associated with melanoma mortality.

**SUMMARY:** Multivariate analysis demonstrated that the presence of >0 to 1 dermatologist per 100,000 people was associated with a 35% reduction in melanoma mortality (95% CI 13.4% to 56.6%) when compared to counties with no dermatologist. The presence of >1 to 2 dermatologists per 100,000 people was associated with a 53% reduction in melanoma mortality (95% CI 30.6% to 75.4%). Having more than 2 dermatologists per 100,000 people did not

further decrease melanoma mortality. Melanoma mortality was also decreased in metropolitan counties (30.3%, 95% CI 17.3% to 43.3%) and in counties where there are hospitals with oncology departments (1.9%, 95% CI 0.6% to 3.1%). Melanoma mortality rates were increased in counties with higher incidence of melanoma (2.3%, 95% CI 1.6% to 3.1%), greater Caucasian population (1.5%, 95% CI 1.1% to 1.9%), and greater health insured populations (1.5%, 95% CI 0.2% to 2.8%). Age, education, income, primary care provider density, health professional shortage area classification, and unemployment rate were not associated with melanoma mortality.

**CONCLUSION:** We found that a greater dermatologist density is associated with a significant reduction in melanoma mortality when compared to counties that lacked a dermatologist.

4:42 – 4:50 pm

**PRESENTER:** Sean R. Christensen, MD, PhD

**TITLE:** **Histopathologic Assessment of Hair Follicle Involvement in Bowen's Disease: Implications for Treatment Approach**

**AUTHORS:** Sean R. Christensen, MD, PhD<sup>1</sup>, Jennifer M. McNiff, MD<sup>1</sup>, Sumaira Z. Aasi, MD<sup>1</sup>, Allison M. Hanlon, MD, PhD<sup>1</sup>, David J. Leffell, MD<sup>1</sup>

**INSTITUTION:** 1. Dermatology, Yale University, New Haven, CT, United States

**PURPOSE:** Bowen's disease (cutaneous squamous cell carcinoma in situ) has been reported to have the potential to extend deeply into the hair follicle and sebaceous gland, but the relative incidence of this feature has not been quantified. Deep follicular extension has been cited as one reason why non-excisional treatment may result in a higher recurrence rate. The purpose of this study was to define the frequency of deep follicular involvement in histopathologic specimens of Bowen's disease.

**DESIGN:** All cases with a diagnosis of Bowen's disease (n = 175) treated with Mohs microscopically controlled surgery (MMCS) at one institution over a six month period were retrospectively reviewed, and cases with positive margins on any stage (n = 60 cases) were selected for analysis. MMCS histopathologic specimens with evidence of Bowen's disease were reviewed by three Mohs surgeons and one dermatopathologist in a blinded fashion and scored for involvement of Bowen's disease in the follicular infundibulum and the deeper pilosebaceous unit below the level of the sebaceous duct. Bowen's disease was defined as disordered epidermal maturation with cytologic atypia affecting the entire thickness of the epidermis. Cases that did not meet criteria for Bowen's disease (n = 7), cases with evidence of invasive squamous cell carcinoma (n = 2), cases without pilosebaceous units within 2 mm of Bowen's disease (n = 8), and cases without preserved tissue specimens (n = 1) were excluded. Pairwise comparison of agreement between

readers was performed with Cohen's kappa coefficient and total agreement between readers was expressed as a percentage.

**SUMMARY:** Four readers scored 42 cases with 59 tissue specimens. The majority of cases were located on the head and neck (88.1%). Bowen's disease involving the deep pilosebaceous unit below the level of the sebaceous duct was observed in 8.33% of cases (range for each reader, 4.76 – 11.9%) and 6.36% of specimens (range, 3.39 – 10.2%). Involvement of the superficial follicular infundibulum was more common, and was observed in 61.3% of cases (range, 19.0 – 81.0%) and 56.4% of specimens (range, 15.3 – 76.3%). A consistent finding in several specimens was prominent cytologic atypia and disordered maturation of the interfollicular epidermis and the upper follicular infundibulum that abruptly normalized just above the level of the sebaceous duct (Figure 1). Concordance among the four readers was variable. Agreement for deep follicular involvement was 69.5%, with pairwise kappa coefficients from -0.012 to 0.210. Agreement for infundibular involvement was 44.4%, with pairwise kappa coefficients from 0.012 to 0.280. There was no significant correlation between deep follicular involvement and lesion size, final defect size, number of Mohs stages or lesion location.

**CONCLUSION:** Deep extension of Bowen's disease along pilosebaceous units is an uncommon finding. Although cytologic atypia and disordered maturation frequently involved the interfollicular epidermis and follicular infundibulum, these changes did not extend below the level of the sebaceous duct in the majority of our cases. This suggests that non-excisional ablative therapies may be appropriate for Bowen's disease in certain clinical situations, as has been suggested in the literature. Further studies will be required to determine the long-term efficacy of such treatments. Intraoperative tissue specimens from MMCS were selected for this study because typical shave biopsy specimens are not of adequate depth to assess the entire pilosebaceous unit. One limitation of the study design, however, is the selective examination of the peripheral margins of the tumor and the inherent assumption that these specimens are representative of the entire lesion. Further studies are planned to assess the entire volume and distribution of Bowen's disease with systematic sampling throughout the tumor.

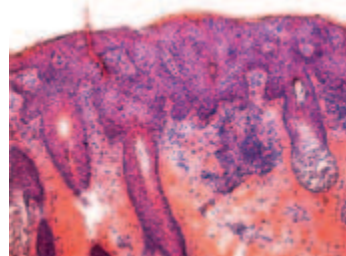


Figure 1. Bowen's disease involving the superficial follicular infundibulum without extension to deeper portions of the follicle.



4:50 – 4:58 pm

**PRESENTER:** William G. Stebbins, MD**TITLE:** Are Patients Satisfied with Second Intention Healing?**AUTHORS:** William G. Stebbins, MD<sup>1</sup>, Victor A. Neel, MD, PhD<sup>2</sup>**INSTITUTIONS:** 1. Dermatology, Vanderbilt University, Nashville, TN, United States 2. Dermatology, Division of Dermatologic Surgery, Massachusetts General Hospital, Boston, MA, United States**PURPOSE:** Second Intention Healing (SIH) has been shown to be a functionally and cosmetically acceptable means of wound healing after Mohs micrographic surgery (MMS), yet there is little research evaluating patient satisfaction during and after the healing process. We sought to compare the patient satisfaction after primary closure versus satisfaction after SIH of surgical defects following MMS for the treatment of non-melanoma skin cancer (NMSC).**DESIGN:** This was a retrospective observational study of 728 patients who underwent MMS for NMSC, followed by either primary closure or SIH. Patients completed a 5-question survey that evaluated satisfaction with physical appearance, difficulty of wound care, and social impact of their wounds during both the short- and long-term post-operative healing periods.**SUMMARY:** Regardless of closure type, the majority of patients demonstrated a high level of satisfaction across all measures in both the short- and long-term post-operative healing periods. Overall, there were no differences in patient satisfaction when comparing primary closure versus SIH.

Factors associated with lower satisfaction scores during the immediate post-operative healing phase included younger age, female gender, increased tumor size, and certain tumor locations (ear, lip, nose, and scalp). Age less than 68 was the only statistically significant predictor of lower patient satisfaction in the long-term post-operative course.

**CONCLUSION:** Second intention healing may be underutilized by Mohs surgeons. Although a good deal of literature exists supporting the use of SIH, this is the first study to evaluate healing by second intention from the patient's perspective. We conclude that, in the majority of patients, second-intention healing is very well-tolerated and results in excellent functional and cosmetic outcomes. In appropriately selected patients, immediate and long-term satisfaction equals that of patients with primarily closed wounds. Furthermore, knowledge of the preferences of certain patient demographics described in this study may help to guide surgeons when deciding the optimal management of a given patient's surgical defect.